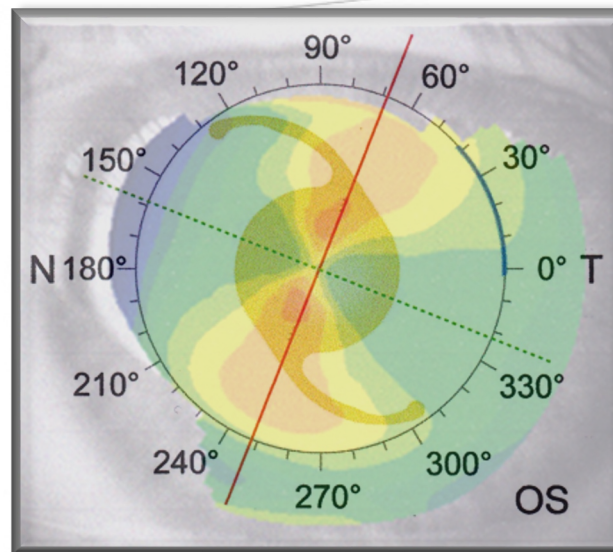


Rotational stability and visual outcome after implantation of the MBI PreciSal aspheric toric intraocular lens



André Dosso, MD, Geneva, Switzerland

Financial disclosure: None

Introduction

Approximately 20% to 30% of patients having cataract surgery have preexisting corneal astigmatism of 1.25 diopters (D) or more (1).

One of the most effective ways to reduce astigmatism at the time of cataract surgery is by implanting toric intraocular lenses (IOLs) (2).

The aim of the study is to evaluate the visual and refractive outcomes and rotational stability of the MBI PreciSal aspheric toric intraocular lens (MBI Millennium Biomedical, Inc.) for the correction of corneal astigmatism in cataract surgery.

Patients and Methods


Prospective clinical study including 15 eyes of 11 patients (mean age of 67.6 years) with a visually significant cataract and corneal astigmatism ≥ 1.5 D and undergoing uncomplicated cataract surgery with implantation of MBI PreciSal aspheric toric IOL.

The method of marking for toric IOL alignment consisted of a manual pendulum-attached marker.

Visual, refractive, and keratometric outcomes as well as IOL rotation were evaluated during a 1-month follow-up. Axis of the lens was assessed postoperatively using the NIDEK OPD Scan III (NIDEK Co Ltd.) at day 1, and day 30.

Results

The mean preoperative keratometric cylinder was 2.41 D (range 1.5 to 3.25) and the postoperative refractive cylinder was 0.44 (range 0 to 0.75). At day one, the mean axis misplacement was 6.3° (range 0 to 12°). At one month, the mean IOL rotation was 1.2° (range 0 to 3°). None of the IOLs required realignment.



Discussion

One factor that determines the effectiveness of the astigmatism correction is the accuracy of toric IOL alignment. Every 5 degrees of misalignment will decrease the anticipated effect by 17% (3).

Such deviations from the intended lens location may be due to inaccuracies in the lens placement or a result of lens rotation (4)

Nowadays two techniques for alignment of toric IOLs can be used, the manual marking techniques or the digital marking system. Interestingly, a recent study shows that IOL misalignment was significantly less with digital marking than with manual marking. However, this did not result in a better UDVA or lower residual refractive astigmatism (5)

Conclusions

Despite a mean misalignment of 6.3 degrees, the residual refractive astigmatism was low, suggesting that the manual-marking technique as well as the excellent positional stability, and the good tolerance of some axis misplacement of MBI Precisal IOL, allow to achieve excellent postoperative outcomes.

References

1. Hoffmann PC, Hütz WW. Analysis of biometry and prevalence data for corneal astigmatism in 23,239 eyes. J Cataract Refract Surg. 2010;36(9):1479–1485.
2. Kessel L, Andresen J, Tendal B, Erngaard D, Flesner P, Hjortdal J. Toric intraocular lenses in the correction of astigmatism during cataract surgery: a systematic review and meta-analysis. Ophthalmology. 2016;123(2):275–286.
3. Novis C. Astigmatism and toric intraocular lenses. Curr Opin Ophthalmol 2000; 11:47-50
4. Hirnschall N, Hoffmann PC, Draschl P, Maedel S, Findl O. Evaluation of factors influencing the remaining astigmatism after toric intraocular lens implantation. J Refract Surg. 2014;30(6):394–400.
5. Valentijn SC et al. Image-guided system versus manual marking for toric intraocular lens alignment in cataract surgery. J Cataract Surg. 2017; 43:781-788.